



PATIENT

Texie Costen

SPECIES

Feline

BREED

DSH

SEX

Female Spayed

AGE

11 years

WEIGHT

11.4lbs

INTERPRETED BY

Maggie Machen Lamy,
DVM, DACVIM
(Cardiology)

IMAGING PERFORMED BY

Meredith Swart, DVM

HOSPITAL NAME

Swart Veterinary
Imaging

REFERRING VET

Dr. Swart

INVOICE

45659

DATE

11/5/25

PRESENTING CLINICAL SIGNS

History: Recheck echo. Historical murmur. Doing well.

-Pertinent previous echo findings (2023 KB): mild asymmetric septal hypertrophy (0.66 cm) with mild SAM most likely consistent with mild HOCM. IVSd: 0.50 cm, LVIDd: 1.6 cm, LVPWd: 0.48 cm, LVIDs: 0.63 cm, LA: 1.17 cm, AO: 1.0 cm, LVOT was not given, RVOT was 2.02 m/s.

ECHOCARDIOGRAM FINDINGS

2D, m-mode, color flow and doppler imaging is available. The left ventricular wall is irregular with mild focal septal thickening and a normal free wall. There is a mildly hyperechoic endocardium consistent with fibrosis. The papillary muscles are mildly hyperechoic. The left atrium is normal in size. The right atrium is normal in size. The right ventricle appears normal. The mitral valve is normal in appearance with trace MR. No TR. Blood flow through the RVOT is normal. The blood flow through the LVOT measures normal; however, mild systolic anterior motion of the mitral valve is suspected on multimodal imaging. No AI. Aortic root is normal. No pleural or pericardial effusion seen. No obvious cardiac tumors.

CARDIAC CHART

FELINE CARDIAC PARAMETERS	BODY WEIGHT (kg)	HR (BPM)	IVSd (cm) (Moise, Pipers)	LVIDd (cm) (Moise, Pipers)	LVWd (cm) (Moise, Pipers)	FS (%)	EF (%)
NORMAL PARAMETER	-----	150-240	0.35-0.55	<2 (mean 1.5)	3.5-0.55	35-67	80-100
PATIENT	5.2	NM	0.62	1.1	0.45	53	87
FELINE CARDIAC PARAMETERS	LA/AO (Boon)	LA/AO HEART BASE (Swe) (Abbott)	LA 2D short axis Base view (cm) (Abbott)		LVOT VEL (m/s)	RVOT VEL (m/s)	E max (m/s)
NORMAL	<1.5	<1.3	<1.2		<1.6	<1.3	<0.9
PATIENT	1.2	1.1	1.1		1.3	1.8	NM

*Note: All measurements based upon multi-modal images and methods. An average value is reported.

Adapted from June Boon, Veterinary Echocardiography, 1998

Abbott J & MacLean H JVIM 2006;20: 111-119, Moise et al. Am J Vet Res 47:1476, 1986. Pipers et al. Am J Vet Res 40:882, 1979.

INTERPRETATION OF THE FINDINGS & FURTHER RECOMMENDATIONS

The cause of the murmur is an LVOT obstruction secondary to abnormal mitral valve motion. The LV is only mildly abnormal, with focal basilar septal hypertrophy, which was noted previously. This likely suggests a normal variant; however, serial monitoring for progressive LVH is recommended. The LA is normal, and no additional issues are identified.

Given these findings, no medications are indicated. Should the degree of hypertrophy worsen, or a more significant obstruction be identified, Atenolol may be recommended in the future.

Prognosis is guarded.

Anesthetic risk is considered mild. Additionally, drugs that stimulate heart rate should be avoided unless clinically necessary (glycopyrrolate, atropine). A reasonable protocol includes opioid/benzodiazepine premedication, propofol induction, isoflurane maintenance. Additionally,



PATIENT

Texie Costen

SPECIES

Feline

BREED

DSH

SEX

Female Spayed

AGE

11 years

WEIGHT

11.4lbs

INTERPRETED BY

Maggie Machen Lamy,
DVM, DACVIM
(Cardiology)

IMAGING PERFORMED BY

Meredith Swart, DVM

HOSPITAL NAME

Swart Veterinary
Imaging

REFERRING VET

Dr. Swart

INVOICE

45659

DATE

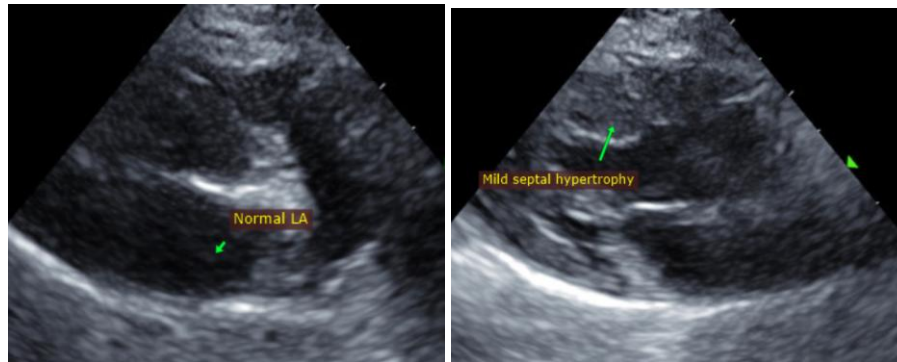
11/5/25

steroids should be used with caution on older cats, as even a 'normal' geriatric heart can develop evidence of intolerance and fluid retention.

Monitor for any development of clinical signs, including labored breathing or signs of a blood clot (paralysis, neurologic change). Prognosis is guarded prior to assessing for progression.

A recheck echocardiogram is recommended in 6-12 months to screen for any evidence of progression.

IMAGES



The information and recommendations provided are based on the images presented by the referring veterinarian. No evaluation can be communicated regarding pathology that was not visible in the image/video clips provided.

Thank you for this referral. This report was generated using transcription software, and minor dictation errors may be present. If the clinical or image interpretation does not parallel your findings or if I can be of any further assistance, please contact me.

Maggie Machen Lamy, DVM
Diplomate of the American College of Veterinary Internal Medicine (Cardiology)
info@sonopath.com